

PREGNANCY DIAGNOSIS (PALPATION)

For cattle producers, it is economically important for cow-calf operations to be as efficient as possible. The producer must consider the costs of maintaining each cow for a year on the basis of the particular operation. The maintenance costs for all cows must be charged against the calf crop during the year. A producer knows that any cow not producing a calf for that year reduces profits considerably. To maintain a successful cow-calf operation, it is necessary for the producer to have a high-percentage calf crop each year.

A technique called palpation* can be used to help the producer determine which cows are not bred. The producer then can cull these cows from the herd and prevent unnecessary costs that decrease returns to the enterprise.

Pregnancy diagnosis is an important tool to measure the success of reproductive management of a cattle herd.


Rectal palpation is probably the most commonly used method for pregnancy diagnosis. Although the technique of palpation is relatively simple, the use of breeding records greatly increases the accuracy of the diagnosis and speeds up the palpation process. Knowledge of when a cow was bred gives the producer some idea as to the stage of pregnancy but only if the cow conceived. Most producers consider rectal palpation to be the fastest and most accurate method to diagnose pregnancy in cattle.

EQUIPMENT NECESSARY FOR PALPATION

Protective Covering for the Palpator

Because the palpator must insert the hand and arm into the cow's rectum, it is necessary to cover those body parts. Plastic sleeves are used for that purpose. It is not necessary to treat plastic sleeves with special care, as they are disposed of after use.

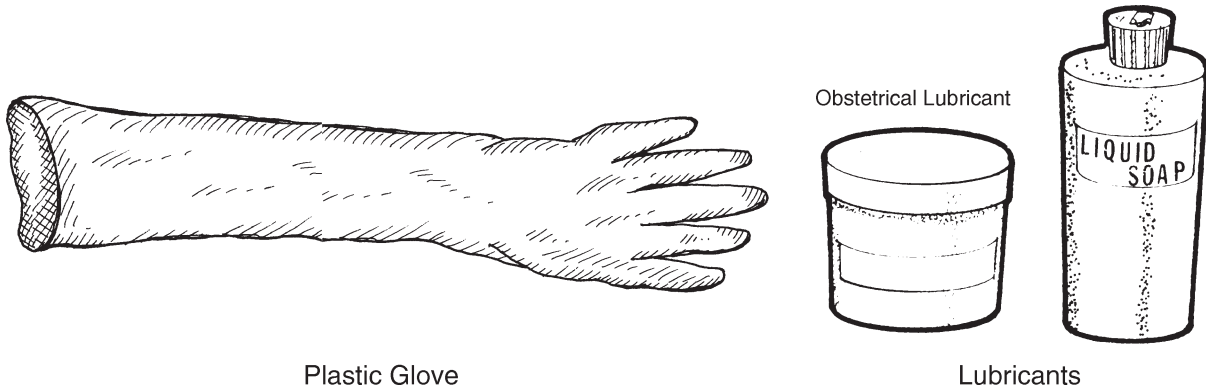
It is also recommended that the palpator wear protective clothing, such as cover-alls and rubber boots.



* Underlined words are defined in the Glossary of Terms.

Lubricant

A lubricant is applied to the covered hand and arm to facilitate entry into the cow's rectum. Commercial obstetrical lubricants are available at farm and ranch supply stores. Liquid soap can also be used as a lubricant, because it provides a slick covering over the arm and does not irritate the cow's rectal cavity as do some detergents.



Chute

The cow should be identified and restrained properly before palpation begins. A holding chute will allow the cow to stand on the ground in a normal position to prevent any unnecessary physical stress. A gate or brace in front of the cow will prevent her forward movement. A pipe or pole should be inserted through the chute behind the cow's legs and approximately four inches above the hocks. The pipe or pole keeps the palpator from being kicked and also prevents the cow from backing. An entrance gate alongside the chute should open to the inside of the chute to close off other cows behind the cow being palpated.

The cow's head should not be placed in a stanchion or head gate, as this tends to excite the cow. If the chute's floor is concrete or wood, then cleats or cross-slats should be constructed to prevent the cow from slipping.

THE REPRODUCTIVE SYSTEM AND PALPATION

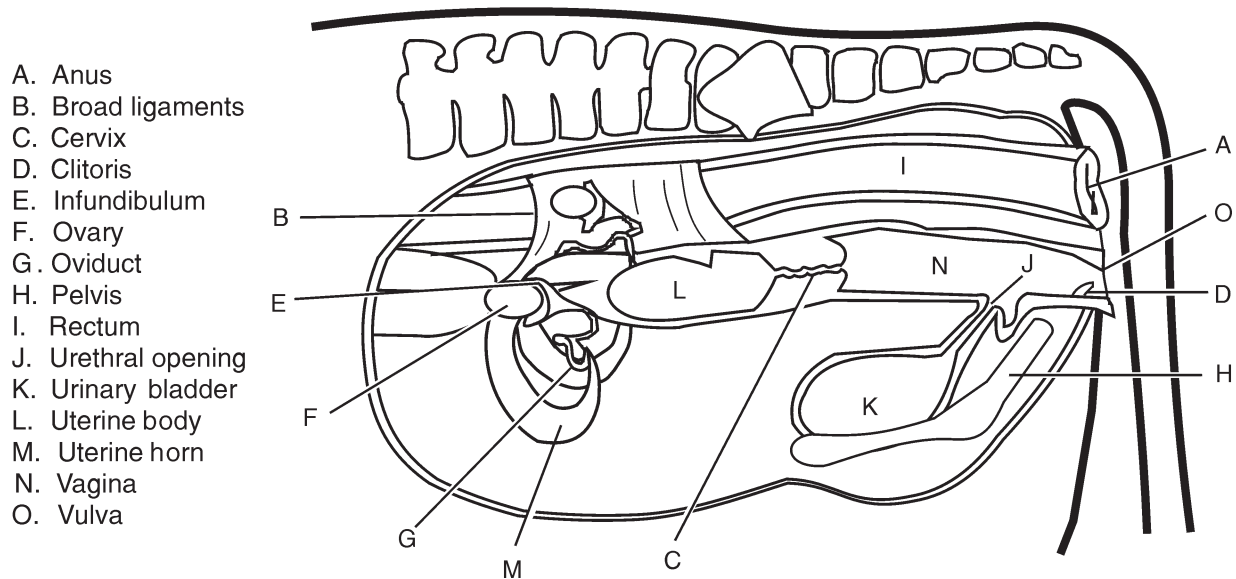
Determining pregnancy in cattle by palpation is not particularly difficult, but it requires experience, practice, and a thorough knowledge of the cow's reproductive system.

To accurately determine pregnancy, the palpator inserts the hand into the cow's rectum, locates the reproductive tract through the rectal wall, and determines whether pregnancy exists by examining the condition of the tract. Because palpation is performed by sense of touch, the palpator must know the location of the cow's reproductive organs and how those organs feel at different stages of pregnancy.

Vulva

The vulva is the external portion of the female reproductive tract. It appears as two prominent, vertical folds of skin beneath the cow's anus. Although of no importance in palpation, the vulva is an indicator of the latter stage of pregnancy. At that time, the vulva is swollen and more prominent.

FEMALE REPRODUCTIVE SYSTEM



Vagina

The vagina is located just inside the vulva and serves as a depository for semen during insemination. The rear portion of the vagina serves as a common passageway for urine from the urethra, and the passage of young at parturition.

The vagina may be the first organ felt during palpation because it is directly under the rectum. The vagina is thin walled and may feel like a soft, spongy cylinder if the palpator is able to feel it at all.

Cervix

The cervix is located at the upper end of the vagina, extending towards the uterus. The cervix is an important “landmark” in palpation, and it usually is easy to locate because of its hard, gristly feel.

Uterus

The uterus lies directly in front of the cervix. The body of the uterus is connected to two uterine horns, which give it its characteristic “Y” shape in cattle. The fertilized egg cell (ovum) implants itself in the wall of one horn. The palpator can follow the two horns by beginning at the upper end of the cervix and following the horns to their respective ends.

A horn is larger at the lower end and tapers in size toward the upper end. Location and feel of the uterine horns depend upon the stage of pregnancy and the cow’s age.

Oviducts

The oviducts (fallopian tubes) are small tubes located at the upper ends of the uterine horns. Each oviduct connects its respective uterine horn to the infundibulum. When the ovary releases an egg, the infundibulum funnels the egg into the oviduct. The oviduct acts as the passageway for the egg as it moves into one of the uterine horns.

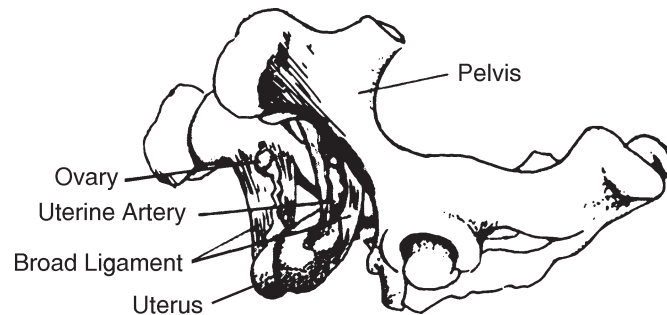
Ovaries

The ovaries suspend in the body cavity by ligaments attached to the top of the abdominal cavity. The ovaries are near the ends of the fallopian tubes on each side of the body cavity. In a normal cow, an ovary is nearly $\frac{1}{2}$ inch wide, $\frac{3}{4}$ inch deep, and 1 inch long. When palpating, the ovary feels firm. The egg develops in a follicle on the ovary wall. A follicle feels similar to a fluid-filled bubble.

Pelvis

The pelvis forms a bone cradle for the reproductive system. As pregnancy advances, the cervix and uterus move down over the pelvic ridge and into the body cavity. Because the pelvis is stationary, it is an excellent “landmark” for the palpator to establish orientation and direction in palpation. The palpator can feel the pelvis by pressing down through the rectal wall.

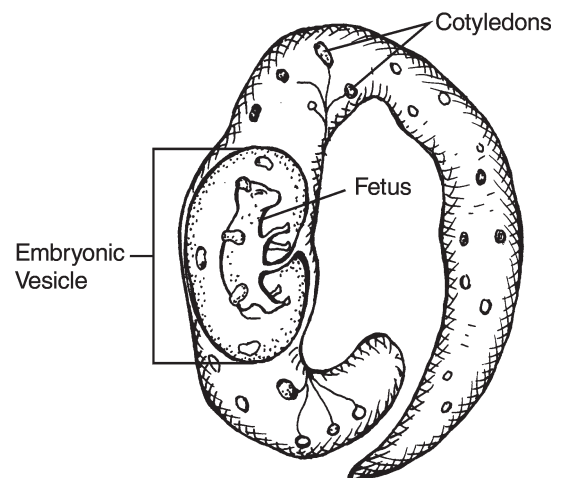
FEMALE REPRODUCTIVE TRACT IN RELATION TO PELVIS



Embryonic Vesicle

After the fertilized ovum has moved into the uterine horn and begins to develop, a fluid-filled sac surrounds it. The embryonic vesicle causes an enlarged area in the horn.

LOCATION OF FETUS IN UTERINE HORN



Cotyledons

Cotyledons are soft, button-like nodules on the fetal membrane that attach to the caruncles lining the uterus during fetal development.

Caruncles

The caruncles are flattened, oval, raised prominences that line the wall of the uterus.

They serve as connecting points for the fetal membranes. After connection, the caruncles serve as nutrient and waste exchange between the fetus and its mother.

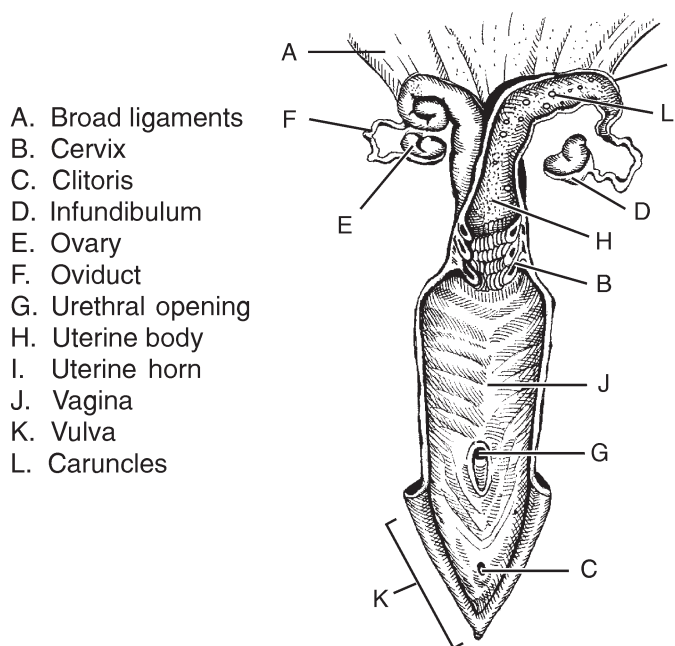
Broad Ligaments

The broad ligaments support the uterus, ovaries, and other organs of the female reproductive tract. The broad ligaments are elastic and allow the reproductive tract to move. They adjust to the increase of weight and size of the reproductive organs during pregnancy. Arteries, veins, and nerves are in these ligaments as well.

Uterine Artery

The uterine artery is the main blood supply to the uterus. The artery supplies each horn and is the main blood supply from the mother to the developing fetus.

CROSS-SECTIONAL VIEW OF COW'S REPRODUCTIVE SYSTEM



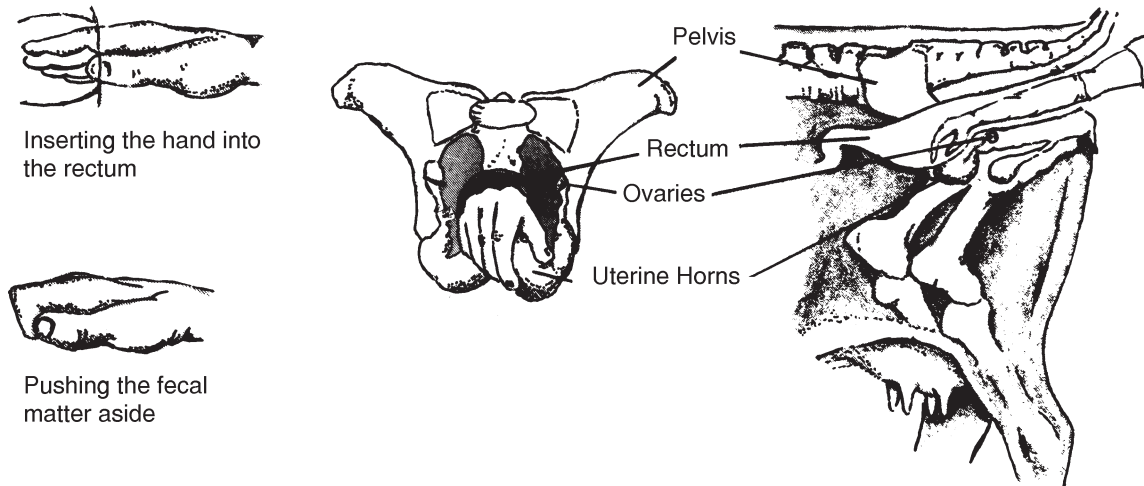
PALPATING

Rectal palpation should be performed with care to avoid damaging the fetus and the cow's rectum. Palpation may be done with either hand. One hand may be used to grasp the cow's tail to use as leverage to push the other hand into the rectum. The covered, lubricated hand should be shaped into a wedge by bringing the fingers close together. The wedge-shape of the hand helps in the initial thrust into the rectum. As the hand goes through the cow's rectum, the hand should be formed into a cone to push aside fecal material and straighten the folds of the rectum.

The cow will naturally strain against the palpator's hand. The palpator should allow the muscle contractions to subside, and then continue pushing the hand through the rectum. Beginning palpators find it helpful to clean the fecal matter from the cow's rectum, as this increases the sense of feel.

Feeling through the rectal wall is similar to feeling through a layer of thin rubber. The thickness varies slightly with individual cows and varies greatly among breeds. The heavier breeds, such as Simmental, Limousin, Chianina, and Maine Anjou, usually have thicker rectal walls than do the smaller breeds. The larger body cavity of the heavier breeds also presents difficulties in locating the reproductive tract after the palpator's hand passes the pelvic ridge. In addition to the breed, the cow's age, condition, and overall size influence the ease of palpation.

POSITION OF THE HAND IN PALPATION



The palpator should locate a point of orientation immediately after entering the rectum. The cervix is an important internal landmark for palpators. Locating the cervix facilitates finding the other organs to be palpated. The pelvic ridge is another helpful internal landmark. If the cow is not pregnant, the reproductive tract normally will lie just to the rear of the ridge. In older cows, the uterine horns of the open tract may hang slightly over the pelvic ridge. As pregnancy advances, the cervix and uterus move over the ridge and into the body cavity, thus requiring the palpator to feel past the ridge and downward.

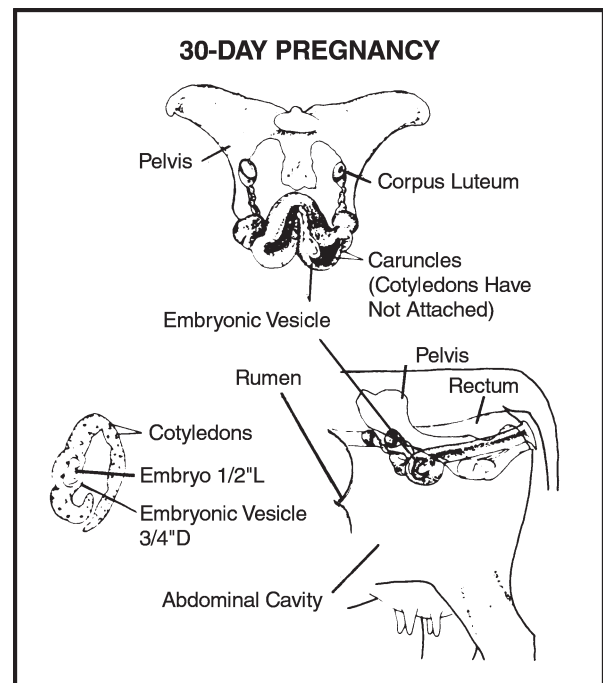
DETERMINING STAGES OF PREGNANCY

30-Day Pregnancy

Determining pregnancy at this early stage takes a great amount of skill and practice. Good breeding records allow the palpator to check the breeding dates of the cows, and these records should be a guide to the palpator at this stage.

In a 30-day pregnancy, the uterus will be filled with fluid and feel slightly thinner. One horn will be enlarged a little more than the other. By running each horn between the fingers, the enlargement in one horn can be felt.

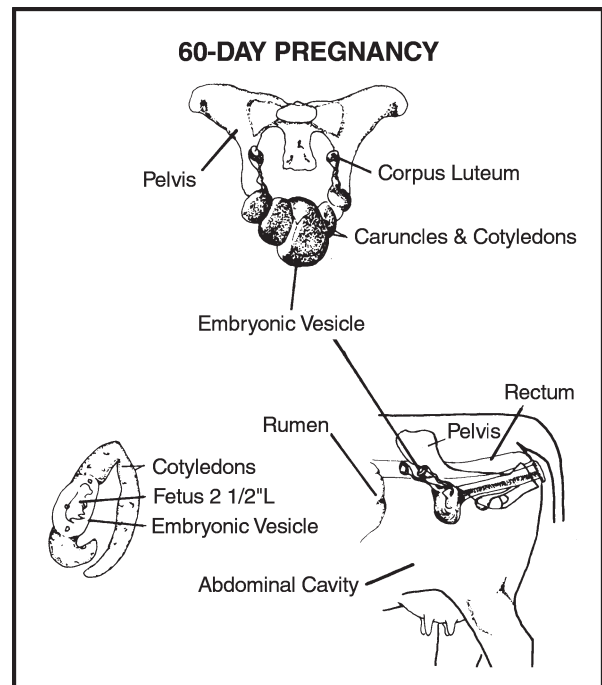
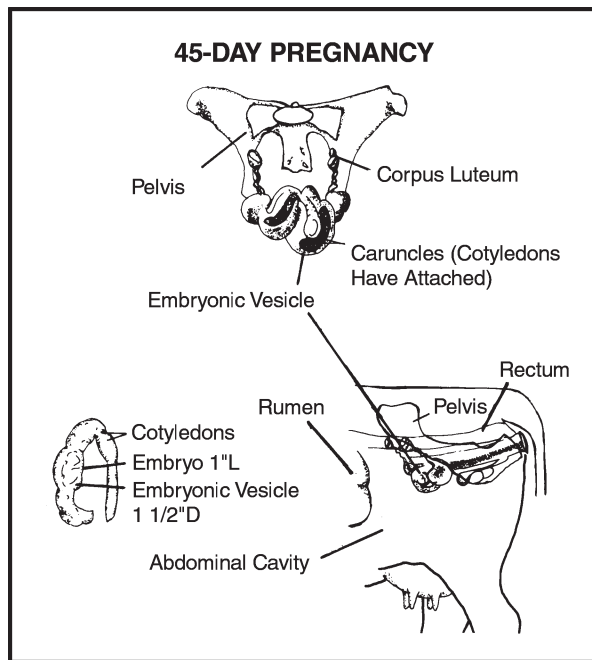
This enlargement in the horn is the embryonic vesicle. The spherical vesicle is nearly $\frac{3}{4}$ inch in diameter and is filled with fluid. It has much the same feel as a balloon filled with water. In most cases, on the side of the uterus (uterine horn) that the vesicle is found, a corpus luteum on the ovary will also be found. The corpus luteum will be a hard teat-like projection on the surface of the ovary. At this stage of pregnancy, the reproductive tract will still lie on the floor of the pelvis.



45-Day Pregnancy

The embryo attaches to the uterine wall on approximately the 38th day. From this time on, it is called a fetus. In this stage, the fetus is nearly one inch long. The vesicle around it is somewhat egg-shaped and measures 1 to 1½ inches in length.

The uterine horn containing the fetus is larger and thinner walled. The vesicle membranes begin to attach themselves to the caruncles on the uterine wall. Therefore, the palpator should be careful and not move the fetus about in the uterus. Excessive movement at this time could break the attachments and cause death of the fetus.



60-Day Pregnancy

The uterus has now enlarged until one horn is approximately the size of a banana and measures 8 to 10 inches long. The weight of the fetus and other contents has pulled the uterus over the pelvic ridge into the body cavity. The fetus measures 2½ inches in length, and the embryonic vesicle is still prominent.

The best method of feeling the fetus at this stage is to gently tap the uterus with your hand. This causes the fetus to swing back and forth and bump against the embryonic vesicle and uterine wall. The palpator can feel the bumping.

In this stage, the cervix is still in the pelvic cradle, and the ovaries suspend rather high in relation to the uterus. The corpus luteum will again be found on the ovary corresponding to the enlarged uterine horn.

90-Day Pregnancy

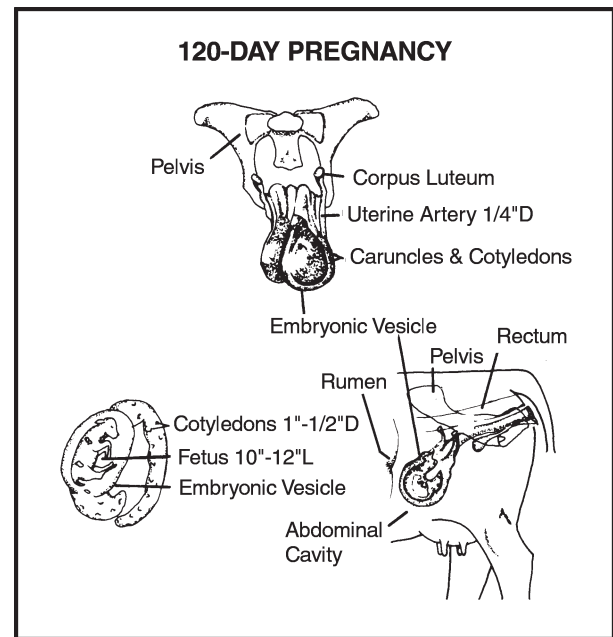
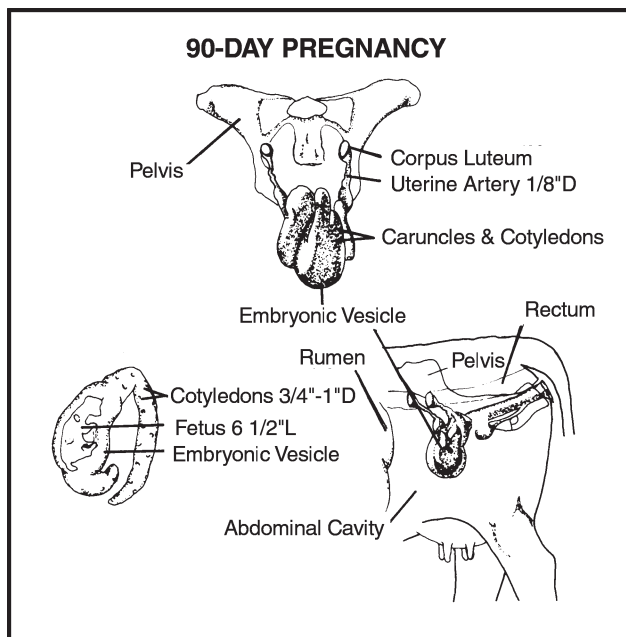
The uterus in this stage is considerably larger because of increased fluid and fetal growth. The fetus is now nearly 6½ inches long and is located on the floor of the body cavity.

The cervix may have pulled itself over the pelvic ridge and into the body cavity. The stretched uterus has pulled the ovaries down. The ovaries may be palpated on either side of the uterus. Because of the low position of the uterus, palpating the fetus in this stage may be difficult.

The palpator may have to consider other factors to confirm pregnancy. The palpation of the uterine artery may be used to accomplish this. This artery, which carries blood to the developing fetus, is located in the forward fold of the ligament that supports the uterus. At this stage, it is $\frac{1}{8}$ to $\frac{3}{16}$ inch in diameter and has a characteristic “whirring” pulsation as the blood moves through it. It can be felt by pressing it against the left forward side of the pelvis. Care must be taken not to confuse the femoral artery, which lies in the muscle of the thigh.

To confirm the presence of the uterine artery, attempt to move it from side to side. The femoral artery cannot be moved and does not have the “whirring” pulsation of the uterine artery.

Perhaps the best indication at this time (in the absence of the fetus) is the presence of the cotyledons on the uterus. They may be felt as flattened, egg-shaped masses on the uterus. A cotyledon feels slightly firmer than the uterus and measures $\frac{3}{4}$ to 1 inch across.



120-Day Pregnancy

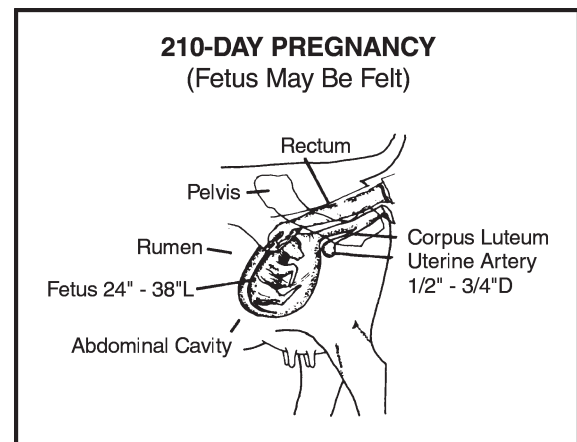
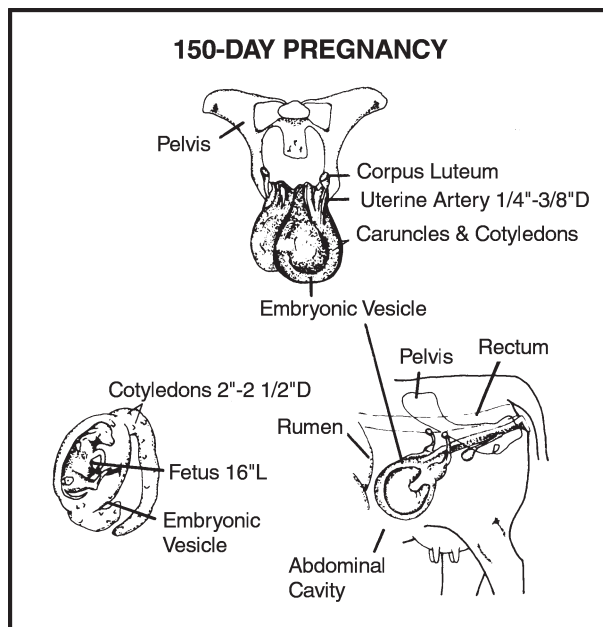
The fetus in this stage is 10 to 12 inches long and is still on the floor of the body cavity. The head of the fetus is nearly the size of a lemon and may be the first portion of the fetus that the palpator touches.

Because the fetus is larger in this stage, it is normally easier to locate. Each cotyledon is 1 to $1\frac{1}{2}$ inches in length, and the uterine artery has increased in size ($\frac{1}{4}$ inch in diameter).

150-Day Pregnancy

The main change from this stage until birth is in the increased size of the fetus. At 150 days, the fetus is the size of a large cat (approximately 16 inches long).

The uterine artery is $\frac{1}{4}$ to $\frac{3}{8}$ inch in diameter, and each cotyledon is 2 to $2\frac{1}{2}$ inches in diameter. Palpation of the fetus still may be difficult because of its low position in the body cavity.



180-Day Pregnancy

At this stage, the fetus is still deep in the body cavity. The uterine artery is $\frac{3}{8}$ to $\frac{1}{2}$ inch in diameter, and the cotyledons are larger.

From 180 days until birth, the fetus can be made to move by grasping its feet, legs, or nose.

Seven-Month and Longer Pregnancy

At 210 days of age, the fetus is 24 to 38 inches long. The uterine artery is $\frac{1}{2}$ to $\frac{3}{4}$ inch in diameter.

From seven months until calving, the fetus may be easily felt because of its increasing size.

OTHER METHODS OF PREGNANCY DIAGNOSIS

Ultrasound

Detection of pregnancy through the use of ultrasound may be beneficial during the later stages of pregnancy (day 30 and later). A probe is passed over the cow's abdominal wall or into the rectum to transmit two-dimensional images to a monitor that can be viewed by a technician. Organs of the reproductive tract, as well as a developing fetus, can be viewed using ultrasound technology.

Biochemical Tests

On-farm test kits are available to producers to pregnancy check their cows. Some test kits are easy to use and give the producer immediate results. One example is a milk progesterone test. This kit allows a producer to test the level of progesterone in a milk sample. A color change in the sample indicates the pregnant or non-pregnant status of the cow.

SUMMARY

Pregnancy diagnosis by palpation is an important tool to measure the success of reproductive management of a cattle herd. Determining pregnancy in cattle by palpation is not particularly difficult, but it requires experience, practice, and a thorough knowledge of the cow's reproductive system to determine the stages of gestation at 30-day intervals.

Additional information about palpation can be found at the following Web sites:

<http://128.192.20.19/LAM/LM000026.html>
<http://virtual.clemson.edu/groups/psapublishing/Pages/ADVS/LL44.pdf>
http://www.alpacaregistry.net/journal/spr2000_03.html
<http://www.dps.ufl.edu/hansen/protocols/palpation.manual.htm>
<http://www.vet.ksu.edu/studentorgs/equine/palpation.htm>
<http://www.wisc.edu/animalsci/facilities/facilities2/pt.html>

Acknowledgements

*Holly Hutton, Graduate Assistant, Department of Agricultural Education,
Texas A&M University, revised this topic.*

*Larry Ermis, Curriculum Specialist, Instructional Materials Service,
Texas A&M University, reviewed this topic.*

*Vickie Marriott, Office Software Associate, Instructional Materials Service,
Texas A&M University, prepared the layout and design for this topic.*

*Christine Stetter, Artist, Instructional Materials Service,
Texas A&M University, prepared the illustrations for this topic.*

REFERENCES

- Dieleman, S. J., et. al. *Clinical Trends and Basic Research in Animal Reproduction*. New York, NY: Elsevier Science, 1992.
- Herman, H. A., Mitchell, J. R., and G. A. Doak. *The Artificial Insemination and Embryo Transfer of Dairy and Beef Cattle*. Danville, IL: Interstate Publishers, Inc., 1994.
- Sorensen, A. M. Jr. *Repro Lab*. 4th ed. Boston, MA: American Press, 1979.

GLOSSARY OF TERMS

Conceived – Became pregnant.

Corpus luteum – A depression on the ovary that occurs after ovulation when the follicle ruptures (if pregnancy occurs, the corpus luteum persists throughout the term and produces the hormone progesterone to keep another follicle from maturing and to develop the mammary system).

Cull – To eliminate an animal from the herd.

Egg cell (ovum) – The egg produced by the ovaries containing the female genes and chromosomes that join with those of the male sperm during fertilization

Embryonic vesicle – A thin membrane filled with fluid and the embryo (serves to protect the embryo and nourishes it until it attaches and becomes a fetus).

Femoral artery – An artery of the hind limb that lies in the muscle tissue (sometimes confused with the uterine artery in palpation but is easily distinguished because it cannot be moved).

Follicle – Contains the immature ova or eggs (during each heat period, one or more mature and rupture at ovulation; also produces the female hormone, estrogen).

Infundibulum – A funnel-like opening that picks up the egg at ovulation and directs it into the body of the oviduct.

Palpation – The procedure of feeling the reproductive tract.

Parturition – The process of giving birth.

Rectum – Terminal segment of the intestinal tract.

SELECTED STUDENT ACTIVITIES

TRUE/FALSE: Circle the “T” if the statement is true or the “F” if it is false.

- | | | | |
|---|---|----|--|
| T | F | 1. | Palpation is the only method used to diagnose pregnancy in cows. |
| T | F | 2. | A palpator uses protective covering and a lubricant when palpating cattle. |
| T | F | 3. | The palpator’s hand locates an orientation point after entering the cow’s rectum. |
| T | F | 4. | Heavier breeds of cattle usually have thicker rectal walls than do smaller breeds. |
| T | F | 5. | The cervix of the cow has a soft, smooth feel. |
| T | F | 6. | The pelvis is a poor landmark for the palpator to use to establish orientation in palpation. |

SHORT ANSWER/LISTING: Answer the following questions or statements in the space provided or on additional paper.

7. Why is palpation important in breeding cattle operations?

8. Why are cattle breeding records beneficial to the palpator?

9. What three major items of equipment are necessary when palpating cattle?

- a.

- b.

- c.

10. How can the palpator differentiate between the uterine artery and the femoral artery of the cow?

ADVANCED ACTIVITIES

1. Develop a research paper describing the origin of palpation as a means of determining pregnancy in livestock.
2. Schedule a field trip to a ranch, auction sale, or other facility to practice palpating cattle using the information presented in this topic.

ALL RIGHTS RESERVED

Reproduction prohibited without written permission.
Instructional Materials Service
Texas A&M University
2588 TAMUS
College Station, Texas 77843-2588
<http://www-ims.tamu.edu>

2002